



New-Onset of Graves' Disease Induced By Sars-Cov-2 Infection- A Case Series

Abhaa Sulaiyam Al-Jahhafi¹, Asma Ali Al-Sawaai¹, Zamzam AL-Bimani² and Naima Al-Bulushi^{2*}

¹Oman Medical Specialty Board (OMSB) radiology residency Program, Oman.

²Nuclear Medicine department and Molecular Imaging Centre, Royal Hospital, Oman.

ABSTRACT

The COVID-19 pandemic had many new post-viral sequelae some of which are yet to be detected. In our case series, we are presenting five patients with different ages, medical backgrounds, and presentations, who were diagnosed with Post COVID-19 Graves' disease at Royal Hospital from January to December of 2020. The main reason behind this case series is to highlight the variability of presentation and the duration between exposure to the virus and the presentation. In addition, due to the similarity in the presentation of some of the symptoms between COVID-19 infection and Graves' Disease, most of those patients were delayed in getting the proper diagnosis of COVID-19-induced Graves' disease. Hence, this case series can aid in alerting primary care doctors for early detection of such cases and regular follow-up, which can positively impact our national healthcare system.

ARTICLE HISTORY

Received 12 May 2023

Accepted 23 May 2023

Published 29 May 2023

KEYWORDS

Graves' disease (GD), COVID-19, Severe acute respiratory syndrome, Coronavirus-2 (SARS-CoV-2).

Introduction

The ongoing pandemic of coronavirus disease (COVID-19) which started in 2019 has been found to have multiple long-ranging effects on the normal physiological balance of the human body. One of these effects is thyroid dysfunction. It is important to emphasize and study the effect of COVID-19 on different organs including the thyroid gland for early diagnosis, proper management, and early prediction of the outcomes. This case series will give a brief summary of our local experience of COVID-19-related Graves' disease at Royal Hospital, Oman.

Material and Method

In this case series, we will present five patients with Graves' disease diagnosed with thyroid scintigraphy that was conducted in the nuclear medicine department at Royal Hospital. Retrospective reviews of the thyroid scans done in our department for patients with thyrotoxicosis from January 2020 to December 2021 with a total number of 176 patients. The inclusion criteria were a history of COVID-19 infection prior to the onset of thyrotoxicosis symptoms, a thyroid uptake scan done in our department, and biochemical evidence of thyrotoxicosis. The Thyroid uptake scans were done in our department by Technetium-99m (TC-99m) pertechnetate using Siemens or GE dual head gamma cameras, with a low energy high-resolution collimator. The patients received a standard dose of 185 MBq of Tc-99m pertechnetate. Anterior and both anterior oblique views were done and the total thyroid uptake as well as the uptake in each thyroid lobe was calculated by the software. The normal range of total thyroid uptake in our department is 0.4 - 4 %.

Results

In our retrospective review, there were ten patients who meet our inclusion criteria. However, we selected five patients to present them as case series to illustrate the different findings in those patients.

Graves' disease diagnosis was based on findings on the thyroid scintigraphy as homogeneously increased radiotracer uptake in the enlarged thyroid gland and abnormally increased global thyroid uptake (above 4%). All scans were reported by a senior nuclear medicine physician. The history of COVID-19 infections was retrieved from electronic medical record (Al-SHIFA system) notes of the referring physicians or from the result of SARS-CoV-2 RNA PCR tests done at Royal Hospital. Other variable data collected were as follows: patient age, gender, symptoms of Graves' Disease and COVID-19 infection, interval time between symptoms of the COVID-19 infection and the onset of Thyrotoxicosis, ultrasound and thyroid scintigraphy findings, and thyroid function test results.

Case 1

A 28-year-old male, not known to have any medical history. Presented to the local health center with upper respiratory tract infection, sore throat, and fever. He was a confirmed case of positive COVID-19 by SARS-CoV-2 RNA PCR in August 2020. He had a mild course of upper respiratory infection disease, which was resolved with supportive care at home. In November 2020, around 4 months later, he presented with a four-week history of palpitation, sweating, heat intolerance, feeling anxiety, and insomnia. Physical examination was positive for hand tremors, tachycardia (heart rate (HR) 130 bpm), and enlargement of the thyroid gland. The labs were significant for TSH: <0.008 m[iU]/L

Contact Naima Al-Bulushi, Nuclear Medicine department and Molecular Imaging Centre, Royal Hospital, Oman.

(normal range:0.55 - 4.78), Free T4: 52.0 pmol/L (normal range:11.5 -22.7), Anti-thyroid peroxidase A: 80.8 [iU]/Ml and thyrotropin receptor antibodies: 5.18 [iU]/L (normal:<1.3). A thyroid ultrasound done outside Royal Hospital showed both thyroid lobes were normal in size with heterogeneous echo patterns. No definite nodules were detected. Color Doppler mapping showed increased vascularity. Thyroid scintigraphy revealed a bulky thyroid gland with diffuse increased radiotracer uptake, Global thyroid uptake was 5.8%. The patient started on carbimazole and propranolol and showed good recovery.

Case 2

A 29-year-old male, not known to have any medical history, presented to the local health center with an upper respiratory tract infection (URTI), sore throat, and fever. He was confirmed to have positive COVID-19 by SARS-CoV-2 RNA PCR in July 2020. He had mild URTI, which was resolved with supportive care at

home. In July 2021 (after one year) the patient presented with a three-month history of weight loss of more than 10 kilograms, heat intolerance, generalized fatigue, weakness, a history of falls at work because of fatigue, and poor appetite. In physical examination, he was found to have hand tremors, tachycardia (HR 120 bpm), enlargement of the thyroid, and bilateral exophthalmos. The labs were significant for TSH: <0.008 m[iU]/L (normal range:0.55 - 4.78), Free T4: 115.1 pmol/L (normal range: 11.5 -22.7), Anti-thyroid peroxidase A: 171 [iU]/Ml and thyrotropin receptor antibodies: 19.31 [iU]/L (normal:<1.3). Thyroid ultrasound showed that the thyroid gland is enlarged with a lobulated outline and shows a coarse heterogeneous echo pattern. No definite focal nodules were seen. On the other hand, Color Doppler mapping showed increased vascularity. The thyroid scintigraphy revealed a bulky thyroid gland with heterogeneity diffuse increased radiotracer uptake and pyramidal lobe. Global Thyroid uptake was 23.0 % (Figure 1).

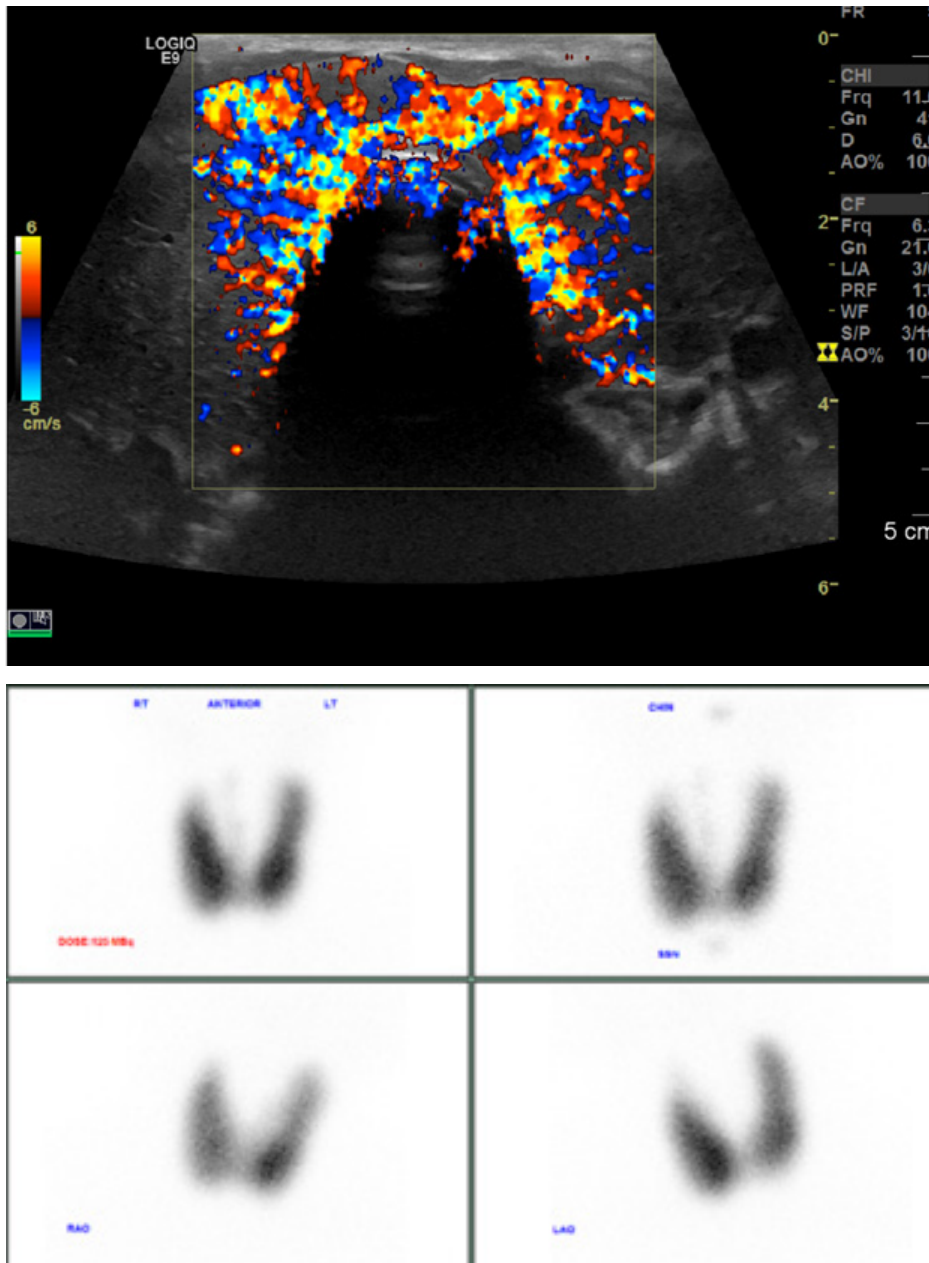


Figure 1: Color Doppler image of the thyroid gland showing hypervascularity (thyroid inferno pattern) {image A}. Tc-99m pertechnetate thyroid scintigraphy, showing a bulky thyroid gland with diffuse increased radiotracer uptake, {image B}.

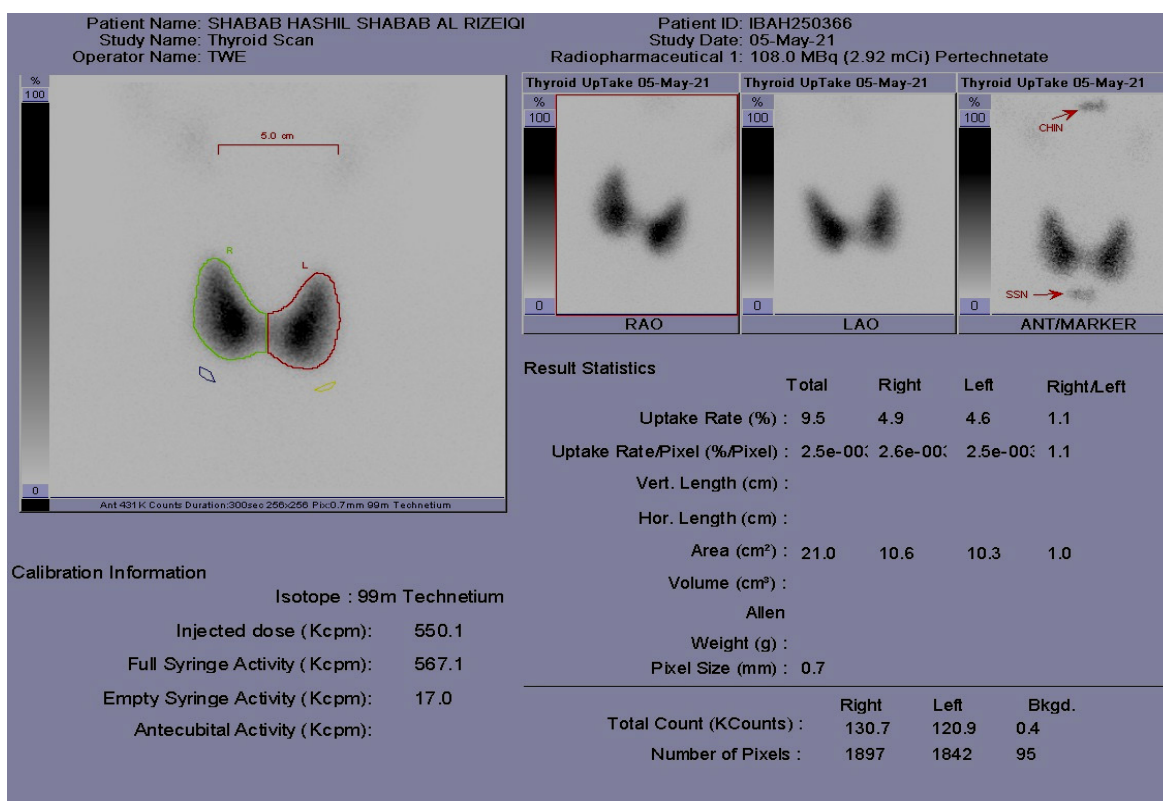


Figure 2: Tc-99m pertechnetate thyroid scintigraphy, anterior view, right anterior oblique view (RAO), left anterior oblique view (LAO), and one view with a marker in the suprasternal notch (SSN) and chin to localize neck area. The scan shows a bulky thyroid gland with diffuse increased homogenous radiotracer uptake. Global thyroid uptake = 9.5% (normal 0.4 – 4%).

Case 3

A 67-year-old male, not known to have any medical history presented to the local health center with a sore throat, cough, and fever. He was a confirmed case of positive COVID-19 by SARS-CoV-2 RNA PCR in February 2020. He had a mild course of the disease, which was resolved with supportive care at home. In April 2020 (two months later), the patient presented to the emergency department with a two-month history of arthralgia, myalgia, and loss of taste then he developed weight loss. On physical examination, the patient was found stable with no tachycardia or hand tremor. The thyroid function test was deranged; TSH: 0.01m [iU]/L (normal range: 0.55 - 4.78), Free T4: 84.4 pmol/L (normal range: 11.5 - 22.7), Anti-thyroid peroxidase A: 187.7 [iU]/mL and thyrotropin receptor antibodies: 25.75 [iU]/L (normal:<1.3). On thyroid ultrasound done outside Royal Hospital, both lobes of thyroid lobes were heterogeneous in texture with areas of hypo-echogenicity interrupted by areas of hyper-echogenicity likely thyroiditis. No definite well-defined focal lesions. On thyroid scintigraphy, it revealed diffusely increased radiotracer uptake in the bilateral thyroid lobes with suppression of the background activity. The global Thyroid uptake was 9.5 % (Figure 2).

COVID infection which was confirmed by COVID-19 by a SARS-CoV-2RNA PCR test. She had a mild fever, cough, and runny nose. She improved with conservative management and did not require hospital admission. On presentation, her examination was unremarkable apart from tachycardia, pulse was 110 bpm. Her blood pressure was normal 131/64 mmHg and was afebrile. She had no neck swelling and no signs of thyroid eye problems. Laboratory evaluation was remarkable for increased levels of T3 and T4 measuring 21.2 pmol/L (normal range 3.5 - 6.5), and 49.1 pmol/L (normal range: 11.5 -22.7), respectively. TSH was very low measuring <0.008 m[iU]/L (normal range:0.55 - 4.78). Anti-thyroid peroxidase A was >1300.0 [iU]/mL. Thyroid ultrasound done outside Royal Hospital revealed diffuse alteration of thyroid echotexture with TI-RADS 2 lesion in left lobe in which FNA was not done. No suspicious neck lymph nodes were noted. Thyroid scintigraphy revealed asymmetric radiotracer uptake in both thyroid lobes. The left lobe shows homogenous significantly increased radiotracer uptake. The right lobe showed heterogeneous radiotracer uptake less than that of the left lobe, and the background activity was partially suppressed. Global Thyroid uptake = 7.8 %. The patient was started on carbimazole and propranolol and showed good recovery.

Case 4

A 45-year-old lady, previously healthy, presented with a 4-month history of palpitation, fatigue, sweating even in cold places, and significant weight loss despite having a normal appetite. She has normal bowel habits. No history of chest pain or shortness of breath. Her period was irregular and lasted for 2 days in 2 monthly intervals. Seven months back, she had a

Case 5

A 25-year-old female with no prior medical history had a fever, cough, and loss of smell and taste for five days. The nasal swab test was positive for COVID-19. The patient had a mild course with no significant respiratory distress. One month later, she started to have palpitation, with no associated fever, neck swelling, or eye abnormality. The lab investigation

Table 1: Summary of data collected for all participants including; Demographic data, timelines between COVID-19 infection and thyrotoxicosis, severity of COVID-19 infection, Laboratory investigation at diagnosis and follow up and global thyroid uptake in thyroid scintigraphy.

Case no	Age	Gender	Timeline between COVID infection and thyrotoxicosis	Severity of COVID infection	Global thyroid uptake	TSH at diagnosis. (0.55-4.78m{IU}/L	T4 at diagnosis. (11.5-22.7 pmol/L)	Thyrotropin receptor antibody. (<1.3 lu/L)	Anti-thyroid peroxidase. [lu]/ml	TSH at follow-up. (0.55-4.78 m {IU}/L	T4 at follow-up. (11.5-22.7 pmol/L)
Case 1	28	M	90 days	Mild	5.8%	< 0.008	52.0	5.18	80.8	3.27	10.5
Case 2	29	M	270 days	Mild	23%	<0.008	115.1	19.31	171	<0.008	26.1
case 3	67	M	concurrent	Mild	9.5%	0.01	>84.37	25.75	187.7	2.69	13.67
Case 4	45	F	30 days	Mild	7.8%	<0.008	>49.1	NA	1300.0	<0.008	16.1
Case 5	25	F	30 days	Mid	6.7%	<0.049	84.11	NA	57.2		

revealed elevated T4 (84 pmol/L with the normal range 12-23), and very low TSH 0.005 m{IU}/L (55 – 5). Ultrasound neck performed outside Royal Hospital showed both thyroid lobes were heterogeneous and bulky with hypervascularity. No focal lesion is noted. On thyroid scintigraphy, there was a bulky thyroid gland with diffusely increased radiotracer uptake and slight suppression of the background activity. Global thyroid uptake was 6.7%. The patient was started on carbimazole and propranolol. In a follow-up OPD visit, she stated that her symptoms resolved.

Discussion

Severe acute respiratory syndrome coronavirus-2 (SARS-CoV-2) is the original virus of COVID-19, which was found to affect several organs and systems including the endocrine system. Thyroid dysfunction was presumed to be a detrimental effect in SARS-CoV-1 and on tissue analysis of the thyroid gland of affected patients there was a finding of extensive injury to the follicular epithelial cells and the parafollicular cells [1]. However, the exact mechanism of how SARS-COV-2 affects the thyroid gland is still controversial and there was published research on the mechanism of thyroid dysfunction and that thyroid damage could result from either a direct or immune-mediated injury [2]. One hypothesis of the pathogenesis of SARS-COV-2 in thyroid dysfunction is injury through internalization of the viral spike protein (S-protein) with their receptor angiotensin-converting enzyme 2 (ACE2) and transmembrane protease serine 2 (TMPRSS2) [3]. The high expression and activation of ACE2 in the thyroid gland led to the likelihood of the effect of the virus in the gland [4]. A retrospective study in Italy reporting the prevalence of thyrotoxicosis post-COVID-19 was found to be 20% [5], which is higher than the expected prevalence of thyrotoxicosis in the general population, which was reported to be 10% [6].

Graves' Disease is an autoimmune disease characterized by a combination of hyperthyroidism, goiter, and thyroid eye disease. It is the commonest cause of thyrotoxicosis [7]. It is caused by autoantibodies to the thyrotropin receptor (TRAb) that activate the receptor, thereby stimulating thyroid hormone synthesis and secretion as well as thyroid growth which consequently causes a diffuse goiter [7].

There are several risk factors attributed to the development of Graves' Disease, one of these is viral infections although there is limited data about the pathogenesis that led to it. With the coronavirus 2019 (COVID-19) pandemic, there has been a

flurry of reports trying to associate infection with autoimmune thyroid disease, and for Graves' disease, only a few case reports were available till the date of this publication.

In this case series, we are summarizing the findings and disease course in patients with thyrotoxicosis secondary to Graves' disease following SARS-Cov-2 infection. All reported cases are new onset of thyrotoxicosis in healthy patients who are not known to have any comorbidities. All cases ran a mild course of Covid-19 infection and were managed conservatively at home. The mean age is 38 years (range 25-67), there is no gender predilection for the disease, and it showed a ratio of to 1:1 male: female. In the current cases, most of the cases occurred after a time interval of an average of 84 days post-confirmed COVID-19 infection (range 30-270 days). Case number 3 showed symptoms of thyrotoxicosis concurrent during an acute illness of COVID-19. However, the symptoms were atypical and non-specified for Graves' disease. The main symptoms were weakness, arthralgia, ageusia, and weight loss, which were all attributed to COVID-19 infection only, hence, leading to a delay in the diagnosis of Graves' disease. This highlights the crucial role of early and frequent evaluation of thyroid profiles in COVID-19-infected patients. Practicing that will influence thyroid disease sequelae and management in those patients [8]. All described cases showed typical features of hyperthyroidism in variable severity and responded well to medical intervention. Graves' disease was diagnosed via laboratory tests and imaging studies including thyroid ultrasound and thyroid scintigraphy. Table 1 summarized all variables analyzed in this series.

Palpitation and fatigue were among the common symptoms observed in our patients, interestingly fatigue/weakness was found to be the commonest symptoms in post covid-19 survivors in one-year follow-up and it accounted for 28 % [9]. Moreover, it has been noticed that as the gap increases between the beginning of hyperthyroidism symptoms and infection the probability of delay in diagnosis increases, as in patient 4 (120 days) and patient 2 (90 days). The average time from symptoms to diagnosis is 55 days (range 30-120). This could be explained by the similarity of the patient's symptoms with reported symptoms as long-term sequelae of COVID-19.

Conclusion

Post COVID-19 infection health sequelae are yet to be clarified and discovered. As far as we know, this is the first case series of such abnormality in our country and in the region. Hence,

we opted to do this case series as we do believe that early diagnosis and treatment of post-COVID-19 Graves' Disease do have a positive impact on the overall well-being of the patients and reduce the long-term side effects of uncontrolled thyrotoxicosis. The authors do recommend more research with a larger number of patients is required to illustrate all the long-term side effects and health sequelae on thyroid function in relation to post-COVID-19 infection.

Reference

1. Wei L, Sun S, Xu C, Zhang J, Xu Y, et al. Pathology of the thyroid in severe acute respiratory syndrome. *Human Pathology*. 2007; 38: 95-102.
2. Gorini F, Bianchi F, Iervasi G. COVID-19 and Thyroid: Progress and Prospects. *International Journal of Environmental Research and Public Health*. 2020; 17: 6630.
3. Lam SD, Bordin N, Waman VP, Scholes HM, Ashford P, et al. SARS-CoV-2 spike protein predicted to form complexes with host receptor protein orthologues from a broad range of mammals. *Scientific Reports [Internet]*. 2020; 10: 16471.
4. Murugan AK, Alzahrani AS. SARS-CoV-2 plays a pivotal role in inducing hyperthyroidism of Graves' disease. *Endocrine*. 2021; 73: 243-254.
5. Lania A, Sandri MT, Cellini M, Mirani M, Lavezzi E, et al. Thyrotoxicosis in patients with COVID-19: the THYRCOV study. *European Journal of Endocrinology*. 2020; 183: 381-387.
6. Carlé A, Andersen SL, Boelaert K, Laurberg P. Management of Endocrine Disease: Subclinical thyrotoxicosis: prevalence, causes and choice of therapy. *European Journal of Endocrinology*. 2017; 176: R325-R337.
7. Sharma A, Stan MN. Thyrotoxicosis: Diagnosis and Management. *Mayo Clinic Proceedings*. 2019; 94: 1048-1064.
8. Allam MM, El-Zawawy HT, Ahmed SM, Aly Abdelhamid M. Thyroid disease and covid-19 infection: Case series. *Clinical Case Reports*. 2021; 9: e04225.
9. Han Q, Zheng B, Daines L, Sheikh A. Long-Term Sequelae of COVID-19: A Systematic Review and Meta-Analysis of One-Year Follow-Up Studies on Post-COVID Symptoms. *Pathogens*. 2022; 11: 269.